



# Severe breathing and swallowing difficulties during routine restorative dentistry

*Ann. Ital. Chir.*  
Published online (EP) 30 April 2015  
pii: S2239253X1502280X  
[www.annitalchir.com](http://www.annitalchir.com)

Filippo Lococo\*, Laura Trabucco\*\*, Giovanni Leuzzi\*\*\* Fulvio Salvo\*\*, Massimiliano Paci\*, Giorgio Sgarbi\*, Anna Maria Ferrari\*\*

\*Unit of Thoracic Surgery, IRCCS-Arcispedale Santa Maria Nuova, Reggio Emilia, Italy

\*\*Department of Emergency Medicine, IRCCS-Arcispedale Santa Maria Nuova, Reggio Emilia, Italy

\*\*\*Department of Surgical Oncology, Thoracic Surgery Unit, Regina Elena National Cancer Institute - IFO, Rome, Italy

## Severe breathing and swallowing difficulties during routine restoration desntistry

Although sporadically reported after dental examination, subcutaneous emphysema may be erroneously confused with an allergic, or anaphylactic, reaction. We herein report a case of a 57-year-old Caucasian woman who came to our attention after restorative treatment for a carious mandibular right second primary molar. During dental examination, an air driven hand-piece was used to restore oclusal caries. Suddenly, swallowing and breathing difficulties and a facial swelling involving the neck and, partially, the face occurred. She was urgently transported to the Emergency Department with the suspicious of allergic reaction. Clinical examination revealed palpable crepitus at the level of the head, neck and pre-sternal region but no inflammation, trismus or fluid collection was detected. A Chest X-ray first and a computed tomography scan later showed air in the deeper regions from the peri-mandibular and retro-mandibular spaces to the sub-maxillary and latero-cervical area along the vascular sulcus and retropharyngeal space descending into the mediastinal space. So, the patient was admitted for respiratory monitoring and started intravenous administration of large-spectrum antibiotics and analgesics. Her hospital course was unremarkable and 5 days later she was discharged after regression of symptoms and complete radiological resolution. Three months after discharge, the patient was clinically free of recurrence.

KEY WORDS: Dental care, Pneumomediastinum, Restorative dentistry

## Introduction

Subcutaneous emphysema is a rare occurrence in dentistry. However, there have been sporadic cases reported following dental treatment that included pulp therapy, extractions, and oral lacerations<sup>2-4</sup>.

## Case report

A 57-year-old Caucasian woman came to our attention after restorative treatment for a carious mandibular right second primary molar. Her medical history was unremarkable. She was a non-smoker and denied dyspnea, dysphagia or recent unintentional weight loss. During dental examination, an air driven hand-piece was used to restore oclusal caries. Suddenly, swallowing and breathing difficulties (cough and increasing dyspnea), and a facial swelling involving the neck and, partially, the face occurred (Fig. 1A). She was urgently transported to the Emergency Department with the suspicious of allergic reaction. On arrival, the patient's vital signs consist-

Pervenuto in Redazione Marzo 2014. Accettato per la pubblicazione Maggio 2014

Correspondence to: Filippo Lococo, M.D. Unit of Thoracic Surgery, IRCCS-Arcispedale Santa Maria Nuova, Reggio Emilia, Via Risorgimento 80, 42100 Reggio Emilia, Italy (E-mail: [filippo\\_lococo@yahoo.it](mailto:filippo_lococo@yahoo.it))

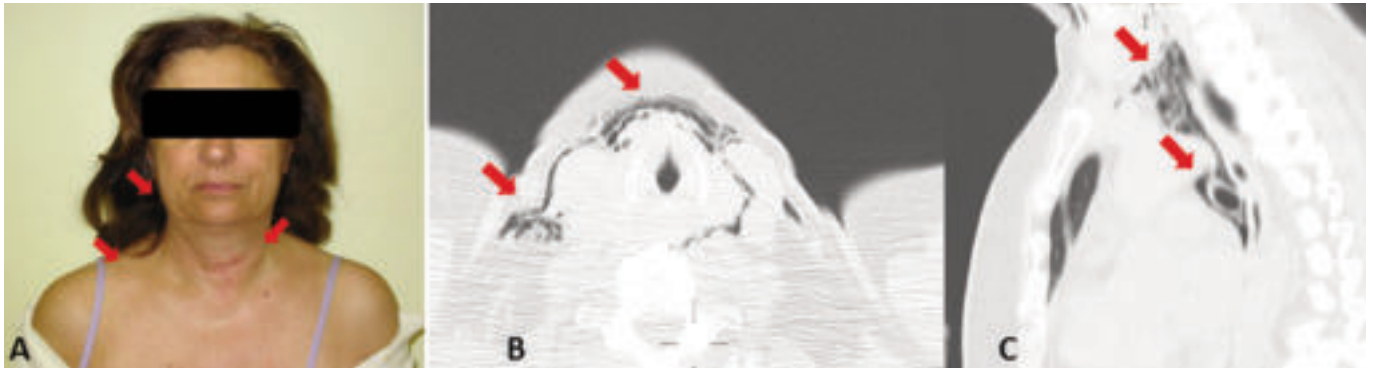


Fig. 1: Clinical onset (Fig. 1A): the patient presented with facial swelling involving the neck and, partially, the face associated with swallowing and breathing difficulties (cough and increasing dyspnea); Radiological Findings: a Chest X-ray first and a computed tomography scan later showed the presence of air in the deeper regions from the perimandibular and retro-mandibular spaces to the submaxillary and laterocervical area along the vascular sulcus and retropharyngeal space (Fig. 1B) descending into the mediastinal space (Fig. 1C).

ed of a blood pressure of 140/80 mmHg (without orthostatic changes), pulse 72 bpm, respiratory rate 17 per minute, and temperature 36.7 °C. She had mild pallor and the skin was warm and dry without cyanosis or rash. Clinical examination revealed palpable crepitus at the level of the head, neck and pre-sternal region but no inflammation, trismus or fluid collection was detected. Thoracic examination revealed a minimal recruitment of accessory respiratory muscles. A Chest X-ray first and a computed tomography (CT) scan later showed air in the deeper regions from the peri-mandibular and retro-mandibular spaces to the sub-maxillary and latero-cervical area along the vascular sulcus and retropharyngeal space (Fig. 1B), descending into the mediastinal space (Fig. 1C); in particular, no signs of pneumothorax were detected. So, the patient was admitted for respiratory monitoring and started intravenous administration of large-spectrum antibiotics and analgesics. Her hospital course was unremarkable and 5 days later she was discharged after regression of symptoms and complete radiological resolution. Three months after discharge, the patient was clinically free of recurrence.

## Discussion

Subcutaneous emphysema is a clinical scenario where air is present subcutaneously. The first definite case of childhood asthma complicated by SE was reported in 1850, although signs and symptoms were recognized by Laennec as early as 1819<sup>1</sup>. In literature, spontaneous occurrences are described after several actions, as playing a musical instrument or tooth extraction<sup>2</sup>. Although sporadically reported after dental examination, subcutaneous emphysema may be mistakenly confused with an allergic, or anaphylactic, reaction<sup>3,6</sup>. In particular, as reported by Steelman and co-workers<sup>7</sup>, the two conditions may be differentiated as follows: in the first clin-

ical scenario, the palpation of the swollen head and neck areas may reveal a crepitus (crunching sound) that is not present in anaphylaxis (as in the present case). On the other hand, despite swallowing and breathing difficulties may occur in both clinical scenario, the abrupt onset of local (pruritis/oedema of lips, tongue and palate) and systemic symptoms (nausea, vomiting, dyspnea, wheezing, syncope and hypotension) are specific and strongly indicative for an allergic/anaphylactic reaction.

Moreover, the patient presented herein had SE that not only involved the head and neck regions but also the mediastinum (see Fig. 1B and 1C). Usually, the origin of the pneumomediastinum remains obscure. It may result from the extension of cervical or thoracic subcutaneous emphysema, or of a pneumo-retroperitoneum consecutive to a visceral rupture. In other cases, it has been attributed to the "Macklin effect". This pathophysiological process, first described by Macklin in 1939 is summed up in three steps: alveolar ruptures, air dissection along bronchovascular sheaths, and spreading of this pulmonary interstitial emphysema into the mediastinum. The Macklin effect is involved in blunt traumatic pneumomediastinum but also in pneumomediastinum arising in various conditions, such as neonate respiratory distress syndromes, asthma crises, positive-pressure mechanical ventilation, and Valsalva maneuvers<sup>8</sup>. Although similarities with this condition can be identified (pneumomediastinum and absence of pneumothorax), in our case the Macklin effect was not the trigger of SE onset. In fact, as theorized by Shackelford<sup>9</sup>, a plausible explanation for the extension of air in the mediastinal space is a communication through submandibular and sublingual spaces, which communicate with the pterygomandibular, parapharyngeal, and retropharyngeal spaces; the mediastinum finally communicates with the retropharyngeal space. As reported by ourselves, the patient underwent a restorative treatment for an occlusal caries by air driven instrument: the air insufflation and

the subsequent increase in atmospheric pressure may have set a suitable condition for the immediate onset of SE, by facilitating the air entry into the submandibular space. In conclusion, this clinical condition may be a complication of odontoiatric treatment, especially when using air driven hand-piece instruments. Generally, even in case of mediastinal involvement, SE is a not life-threatening event, that usually resolves spontaneously, and leaves no permanent sequelae. Nevertheless, a correct diagnosis and a differential diagnosis with allergic reaction is imperative; moreover, clinical monitoring and large-spectrum antibiotics are recommended <sup>7</sup>.

### Riassunto

Una donna di 57 anni si sottoponeva ad trattamento odontoiatrico per una carie del secondo molare superiore di destra. Durante la visita odontoiatrica veniva utilizzato uno strumento ad aria compressa, secondo lo standard di cura. Improvvisamente, la paziente accusava deglutizione e difficoltà respiratorie ed un notevole gonfiore del viso che coinvolgeva il collo e parzialmente il volto. La paziente veniva pertanto trasportata d'urgenza al Pronto Soccorso con il sospetto di reazione allergica. L'esame clinico rivelava un crepitio palpabile a livello dei tessuti sottocutanei del volto, del collo e della regione pre-sternale senza però rilevare nessun segno di infiammazione, trisma o raccolta di liquidi. Una radiografia del torace prima ed una tomografia computerizzata successivamente confermavano la presenza d'aria nei tessuti molli delle regioni profonde dagli spazi peri-mandibolare e retro-mandibolari e nella zona sub-mascellare e latero-cervicale estendendosi lungo il solco vascolare e nello spazio retrofaringeo discendente fino a livello del mediastino. La paziente veniva quindi sottoposta ad osservazione clinica e monitoraggio respiratorio, e si cominciava la somministrazione endovenosa di antibiotici ad ampio spettro ed analgesici. Il successivo decorso ospedaliero risultava regolare e la paziente veniva dimessa in 5° giornata di ricovero dopo miglioramento del quadro clinico e radiologico. Tre mesi dopo la dimissione, la paziente risultava in buone condizioni cliniche in assenza di recidiva.

Come risulta nel caso sopra riportato, l'enfisema sottocutaneo e lo pneumomediastino, sebbene raramente possono essere legati ad alcune manovre odontoiatriche che utilizzano sistemi ad immissione di aria ad alta pressione. Nonostante l'esordio acuto ed la sintomatologia spesso allarmante (al punto da poter essere erroneamente scambiata per una reazione allergica), si tratta di una condizione benigna e sostanzialmente ad auto-risoluzione pur necessitando di un breve periodo di osservazione clinica e profilassi antibiotica.

### References

1. McGovern JP, Ozkaragoz K, Roett K, Haywood TH, Hensel Jr A: *Mediastinal and subcutaneous emphysema complicating atopic asthma in infants and children; Review of the literature and report of occurrence in an infant two years of age*. Pediatrics, 1961; 27:951-60.
2. Parker GS, Mosborg DA, Foley RW, et al.: *Spontaneous cervical and mediastinal emphysema*. Laryngoscope, 1990; 100:938-40.
3. Torgay A, Aydin E, Celasun U, Durmaz L, Arslan G: *Subcutaneous emphysema after dental treatment: A case report*. Pediatr Anaesth, 2006; 16:314-17.
4. Sood T, Pullinger R: *Pneumomediastinum secondary to dental extraction*. Emer Med J 2001; 18:517-18.
5. Durukan P, Salt O, Ozkan S, Durukan B, Kavalci C: *Cervicofacial emphysema and pneumomediastinum after a high-speed air drill endodontic treatment procedure*. Am J Emerg Med, 2012; 30(9):2095.e3-6. doi: 10.1016/j.ajem.2012.01.006. Epub 2012 Feb 4.
6. Salib RJ, Valentine DLO, Atchtar S: *Surgical emphysema following dental treatment*. J Laryngol Otol, 1999; 133:756-58.
7. Steelman RJ, Johannes PW: *Subcutaneous emphysema during restorative dentistry*. Int J Paediatr Dent, 2007; 17(3):228-29.
8. Wintermark M1, Schnyder P: *The Macklin effect: a frequent etiology for pneumomediastinum in severe blunt chest trauma*. Chest, 2001; 120(2):543-47.
9. Shackelford D, Casani J: *Diffuse subcutaneous emphysema, pneumomediastinum and pneumothorax after dental extraction*. Ann Emerg Med, 1993; 22:248-250.