

A rare case of complicated Meckel's diverticulum.

Case report and images.



Ann. Ital. Chir., 2010 81: 449-451

Marco Caricato*, Giuseppe Mangiameli*, Federica Miccadei**, Gianfranco Bulzomi**, Roberto Coppola*

*Department of Surgery, Università Campus Bio-Medico di Roma, Rome, Italy

**Struttura Complessa di Chirurgia Generale, Ospedale di Assisi, Assisi (PG), Italy

A rare case of complicated Meckel's diverticulum. Case report and images

INTRODUCTION: *Gastrointestinal stromal tumors (GISTs) are the most common mesenchymal tumors of the gastrointestinal tract, and account for 0.1%-1% of gastrointestinal malignancies. Meckel's diverticulum (MD) is the most prevalent congenital abnormality of the gastrointestinal tract (0.3%-4.0%).*

DISCUSSION: *Their clinical presentation is strongly related to the occurrence of complications or the development of a neoplasm. Tumors and perforation of MD are infrequent.*

The case presented here is to our knowledge the fourth published case of a small intestine GIST causing perforation of the Meckel's diverticulum.

CONCLUSION: *Although there is no compelling evidence in the current literature to support prophylactic diverticulectomy for patients with MD, our and other similar cases could justify the use of simple laparoscopic tangential resection during elective operations for healthy patients.*

KEYWORDS: Gastrointestinal stromal tumors, Intestinal perforation, Meckel diverticulum.

Background

Gastrointestinal stromal tumors (GISTs) are the most common mesenchymal tumors of the gastrointestinal tract, and account for 0.1%-1% of gastrointestinal malignancies. The term GIST was originally used in 1983 by Mazur and Clark¹. The definition, however, was revised in 1998, so that now only cellular spindle cell, epitheloid, and pleomorphic mesenchymal tumors of the gastrointestinal tract that stain positive for CD 117 are termed GISTs. They occur predominantly in adults at a

median age of 58 years. GISTs typically arise in the bowel wall between the muscularis propria and the muscularis mucosa. Liver (65%) and peritoneum (20%) represent the most common sites of distant metastases. Lymphatic spread is uncommon.

Meckel's diverticulum is the most prevalent congenital abnormality of the gastrointestinal tract (0.3%-4.0%). The vast majority of MD cases are discovered incidentally during autopsy, laparotomy, or barium studies. MD is surgically removed only when a complication arises or a neoplasia develops. The lifetime complication rate for MD is around 4%. Tumors are infrequent, and are observed in only 0.5%-3.2% of MD cases. Of these tumors, 12% are GISTs². Of the complications reported, perforation occurred in 7.3%-14% of cases. Tumors rarely led to perforation. To our knowledge, since 1978 only 4 cases of GIST-associated perforation of a MD have been reported³⁻⁶. We report here a case of GIST causing MD perforation.

Pervenuto in Redazione Luglio 2010. Accettato per la pubblicazione Agosto 2010

Correspondence to: Giuseppe Mangiameli, MD, Università Campus Bio-Medico di Roma, Department of Surgery, Via Álvaro del Portillo 200, 00128 Rome, Italy (e-mail: g.mangiameli@unicampus.it)

Case report

A 65-year-old male diabetic patient, never submitted to abdominal surgery, presented with severe abdominal pain. Abdominal plain X-rays revealed pneumoperitoneum. A computerized tomography (CT) scan confirmed pneumoperitoneum and showed the presence of a 4 cm solid mass of presumable jejunal origin. Enlarged retroaortic nodes were also detected. An exploratory laparotomy was performed, and a perforated Meckel's diverticulum with flogistic involvement was found, 44 cm proximal to the ileocecal valve. The involved ileal segment was excised (Fig. 1), and a manual latero-lateral anastomosis was performed. The pathology report showed a 6 cm small bowel loop with a perforated diverticulum 4.5 x 3.7 x 3.5 cm in size. Cut section through the diverticulum showed a firm white mass with small areas of hemorrhage occupying the whole lumen. Tumor cells showed positive reaction to CD 117, CD 34 and AML. Mitotic activity was estimated to be 1 mitosis per 50 high-power fields (Fig. 2). A GIST arising in the MD was diagnosed, with surgical margins and the 2 mesenteric lymph nodes free from tumor involvement. The postoperative course was uneventful, and the patient was discharged on the 12th postoperative day. No adjuvant treatment was administered. At 2 years follow-up the patient is well, with no signs of recurrence.

Discussion

MD is the most commonly encountered congenital anomaly of the small intestine, occurring in approximately 2% of the population. It is located on the antimesenteric border of the ileum, approximately 40 to 60 cm proximal to the ileocecal valve, and results from incom-

plete closure of the omphalomesenteric or vitelline duct. The vast majority of MD are discovered incidentally during laparotomy, autopsy or barium studies. Their clinical presentation is strongly related to the occurrence of complications or the development of a neoplasm. The most common complications associated with MD are gastrointestinal bleeding, intestinal obstruction⁷, and diverticulitis. The presence of ectopic pancreas in MD is often an accidental finding sometimes related to symptoms⁸. Less than 10% of symptomatic MD are diagnosed preoperatively because they can mimic several other gastrointestinal disorders. Appendicitis, however, represents the most common preoperative diagnosis in cases of complicated MD. Tumors within a MD are rare, with a reported frequency of 0.1% to 3%, and most are benign. Adenocarcinoma (commonly originated from etherotopic gastric mucosa), sarcoma, carcinoid tumors and GIST are the most common malignant neoplasms. The case presented here is to our knowledge the fourth published case of a small intestine GIST causing perforation of the Meckel's diverticulum. In this case, the patient's neoplasia did not show high malignancy characteristics with regard either to tumor size or to mitosis number. Resection margins were negative, and no distant metastases were identified by CT.

Conclusion

Neoplasms arising from Meckel's diverticulum are rare. Although there is no compelling evidence in the current literature to support prophylactic diverticulectomy for patients with MD, our and other similar cases could justify the use of simple laparoscopic tangential resection during elective operations for healthy patients.

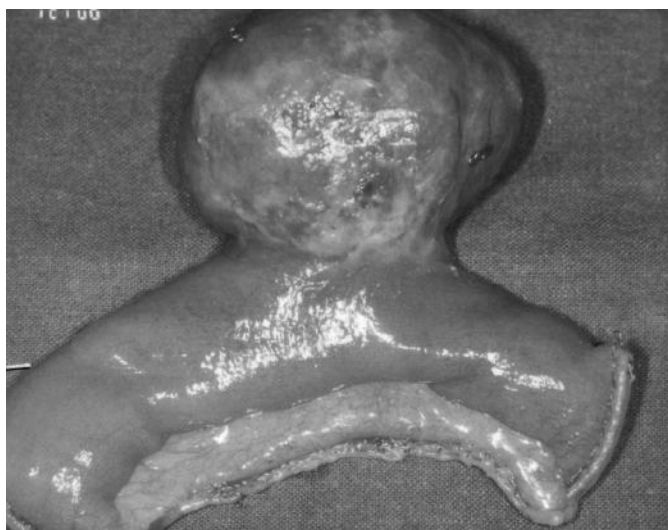


Fig. 1: Operative specimen.

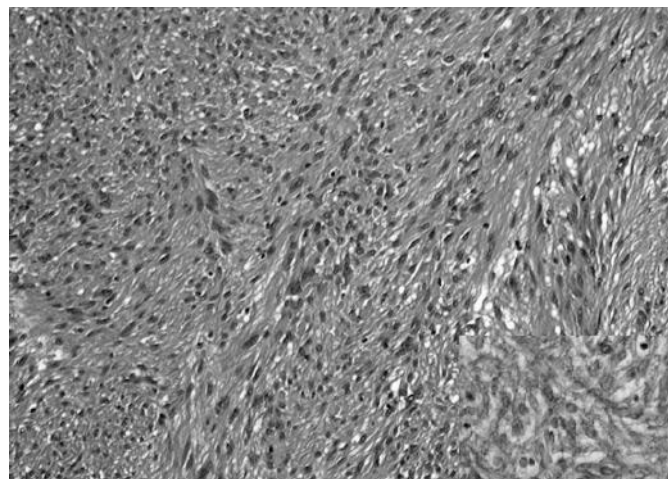


Fig. 2: Standard histology shows a population of spindle cells arranged in interlacing bundles (H&E, x100). The cells are diffusely positive for C-Kit immunostaining (insert, x200).

Riassunto

I tumori stromali gastrointestinali (GIST) sono neoplasie di origine non epiteliale che interessano il tratto gastrointestinale, e rappresentano solo lo 0,1-1% dei tumori maligni gastrointestinali. Il Diverticolo di Meckel è la più frequente anomalia congenita del tratto gastrointestinale (0,3-4 %), con sintomatologia essenzialmente riconducibile alle sue complicanze. Tumori e perforazioni del diverticolo di Meckel sono rare manifestazioni. Di seguito riportiamo un caso clinico di GIST su diverticolo di Meckel, diagnosticato in corso di laparotomia esplorativa d'urgenza per perforazione dello stesso.

References

- 1) Mazur MT, Clark HB: *Gastric stromal tumors. Reappraisal of histogenesis*. Am J Surg Pathol, 1983; 7(6):507-19.
- 2) Lorusso R, Forte A, Urbano V, Soda G, D'Urso A, Bosco M.R, Mancini P, Bezzi M: *Small bowel stromal tumors in a "meckelian" location. About a clinical observation*. Ann. Ital. Chir. 2003; 74(6):707-11.
- 3) Fruhauf C, Garcia A, Rosso R: *Stromal tumor in a perforated Meckel's diverticulum: A case report*. Swiss Surg, 2002; 8(6):273-276.
- 4) Szentpáli K, Palotás A, Wolfárd A, Tiszlayicz L, Balogh A: *A gastrointestinal stromal tumour presenting in a perforated Meckel's diverticulum*. Can J Surg, 2004;47(1):70.
- 5) Hager M, Maier H, Eberwein M, Klinger P, Kolbitsch C, Tiefenthaler W, Mikuz G, Moser PL: *Perforated Meckel's diverticulum presenting as a gastrointestinal stromal tumor: a case report*. J Gastrointest Surg, 2005; 9(6):809-11.
- 6) de la Morena López F, Fernández-Salazar L, Velayos B, Aller R, Juárez M, González JM: *Meckel's diverticulum and gastrointestinal stromal tumor: An unusual association*. Gastroenterol Hepatol, 2007; 30(9):534-37.
- 7) Tosato F, Corsini F, Marano S, Palermo S, Piraino A, Carnevale L, Scocchera F, Vasapollo L, Paolini A: *Ileal occlusion caused by enterolith migrated from Meckel's diverticulum*. Ann Ital Chir, 2000; 71(3):393-6.
- 8) Maggi G, Navarra L, Cianca G, Vittorini V, Ciccarelli O, Pietroletti R, Ierace A, Sindici G: *Ectopic pancreas in Meckel's diverticulum: a description of a new clinical case*. Ann Ital Chir. 2002; 73: 647-50.