

Colovesical fistula in sigmoid diverticulitis

A case report



Ann. Ital. Chir., 2013 84: 477-481

Published online 30 August 2012

pii: S0003469X12019136

www.annitalchir.com

Roberto Fiori**, Luciano Izzo*, Annarita Forcione*, Antonio Bolognese*, Sara Izzo*,
Giovanni Nano**, Isabelle Di Poce**, Giovanni Simonetti**

*Dipartimento di Chirurgia P. Valdoni Policlinico Umberto I, Roma, Italy

**Dipartimento di Diagnostica per immagini, Imaging Molecolare, Radiologia Interventistica e Radioterapia Policlinico di Tor Vergata; Roma, Italy

Colovesical fistula in sigmoid diverticulitis. A case report

Colonic diverticulosis has continuously increased, noticeably left-sided disease. Colovesical fistula is an uncommon complication of diverticulitis, and its most common cause is diverticular disease. Pneumaturia and fecaluria are commonly related symptoms. We present the case of a 79-year-old woman complaining pneumaturia and fecaluria. Abdominal CT showed a colovesical fistula due to sigmoid diverticulitis. After surgical adhesiolysis between the sigmoid colon and the bladder, the defect of the bladder wall was repaired by simple closure. The colonic defect was treated by segmental resection including the rectosigmoid junction. Following the operation the patient continuously improved at months 6, 12 and 18 without evidence of recurrences.

KEY WORDS: Colonic diverticulitis, Intestinal Fistula, Sigmoid colon

Introduction

Colonic diverticulosis refers to a small outpouching of the intestinal wall. It is classified histologically as true diverticula, in which all layers of the bowel wall protrude, or as false diverticula, in which only the mucosal and submucosal layers protrude through the muscular layer. True diverticula are hereditary and develop more commonly in the right colon. In contrast, false diverticula are acquired diverticula due to degenerative changes of the bowel wall with aging and the lack of a high fiber diet, occurring frequently in the left colon. The incidence of colonic diverticulosis is high in the

western countries where diet fibers are consumed less. Reports on sigmoid colonic diverticulosis related colovesical fistula complication are very rare. Also in the Korean medical database, we found only two papers^{1, 2}. Recently, at our hospital, one case of sigmoid colovesical fistula caused by diverticulitis happened, and here we present a review of that case, along with a review of the literature.

Case report

A 79-year-old woman was admitted at our hospital complaining fecaluria and pneumaturia started a week earlier. Her medical history reported that two years earlier she visited a private clinic for the chief complaint of frequent urination and cystitis was diagnosed. Hence, she was successfully treated by antibiotics for 2 weeks; at that time she was currently on antihypertensive drugs and aspirin for hypertension. During the past 5 years, she had been taking drugs for hip joint arthritis with ambulating compromise, she used a wheelchair.

Pervenuto in Redazione Marzo 2012. Accettato per la pubblicazione Luglio 2012

Correspondence to: Prof. Luciano Izzo, General Surgery Unit, P. Valdoni Department, University of Rome "La Sapienza", Viale del Policlinico 150, 00161. Roma (e-mail: luciano.izzo@uniroma1.it)

At the time of admission at our hospital signs other than the fecaluria and pneumaturia were not reported. At physical examination mild tenderness in the left lower quadrant was detected without rebound tenderness or palpable masses, fever or chill were not detected. Vital signs were normal.

Urine was macroscopically opaque with positive nitrite reaction. On microscopic examination, leucocytes and bacteria were observed. Culture tests were positive for *E. coli*.

Abdominal CT scans showed gas within the bladder. Sigmoid colon wall and bladder dome appeared closely adherent and thickened and nearby adipose tissue effusion were evident. Nevertheless, no abscess or fistular tract was observed (Fig. 1). To assess the fistular tract, we performed cystography, but the fistula was not seen. A barium enema showed that along the fistula, dyes entered from the sigmoid colon to the bladder, and in the sigmoid colon, multiple diverticula were present (Fig.

2). On colonoscopic examination, hyperemic mucosal lesions, which were suspected to be diverticula, were detected in the area about 40 cm above the anal verge, and no special finding, which could be suspected of being a fistula or malignancy was observed.

Based on the above examinations, diagnosis of sigmoid colovesical fistula caused by diverticulitis was made, and open abdominal surgery was performed. In operative findings, the distal sigmoid colon was severely adherent to the dome of the bladder and overall to the base, thus, the location of the fistula could not be assessed. Unavoidably, the bladder was incised, and a fistula located between the two ureteral openings was found. Because of the concern of possible ureteral injury, a double J catheter was inserted, and the surgery proceeded. First, the bladder and the sigmoid colon were separated, and after curettage, primary repair was performed on the fistular area of the bladder, and a segmental resection was performed on the colon, including the recto-sigmoid colon junction. In the resected sigmoid colon tissues, an abscess and a fistula caused by diverticulitis were observed. Diet was initiated from seven days after surgery, and no special problems developed. On day 14, to confirm the absence of bladder leakage, we performed cystography in order to remove the catheter. On day 17, the patient was discharged after removal of the catheter, and during the follow-up observation at 6, 12 and 18 months after surgery, no complications or evidence of recurrence were observed.

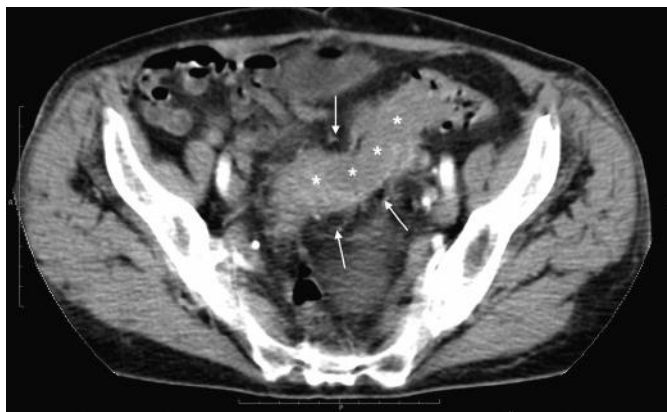


Fig. 1: X – CT axial slice showing the fluid filled sigmoid colon lumen (asterisks) and the outpouching sigmoid diverticula (arrows).

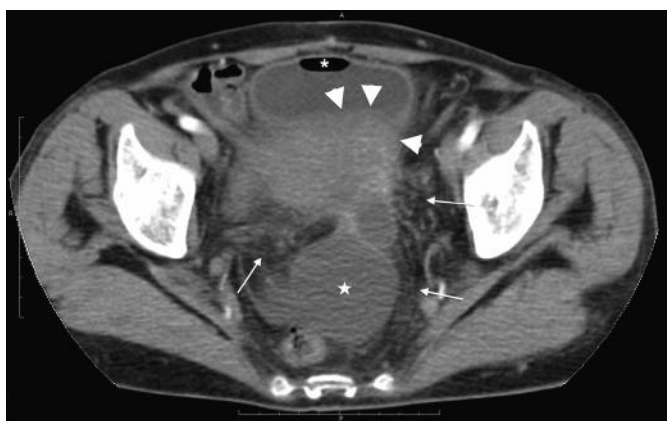

Fig. 2: Y – CT axial slice showing the bowel-bladder thickened walls (arrowheads) with consensual surrounding adipose tissue effusion (arrows). Air-fluid level is clearly evident inside the bladder (asterisk) and reactive fluid trasudate inside the Douglas pouch (star).

Discussion

Colonic diverticulosis occurs with high frequency in western countries where food containing low fiber content is consumed, but it is not common in Korea. However, recently, the incidence is on the rise even in Korea. This may be due not only to diverticulosis actually occurring more frequently due to the increased elderly population and the westernization of diet but also to the increased detection rate by the spreading colonoscopy, abdominal computed tomography and other diagnostic methods, as well as active examination³.

In western countries, with aging, the incidence has increased. In the group younger than 40 years of age, the incidence of diverticulosis has been reported to be lower than 5%. On the other hand, in the group older than 80 years of age, it is 65%⁴. In Korea, the incidence in the general population has not been investigated. Nonetheless, among approximately 9,000 patients who received a colonoscopic examination, diverticulosis was reported to have been detected in 7.3% of the patients⁵. Approximately 10-20% of people with diverticula have been reported to develop diverticulitis, 10-20% of which have been reported to require hospitalization. It has been reported that 20-50% of the hospitalized diverticulitis patients required surgery; thus, ulti-

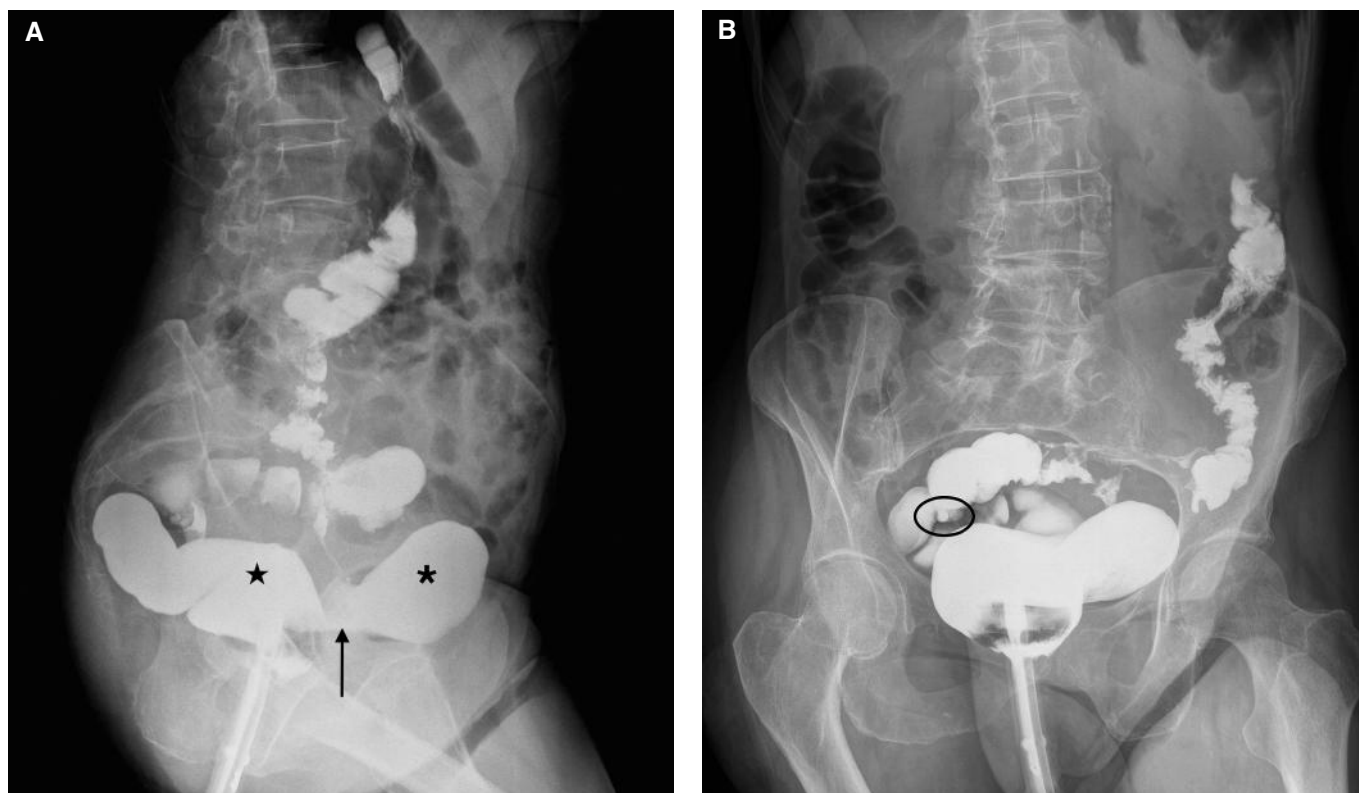


Fig. 3: (A) LL and AP (B) roentgenograms showing the fistular tract (arrow) with extravasation of barium sulfate from bowel (star) to bladder (asterisk). Diverticula are evident along the whole sigmoid-descending colon (oval).

mately, surgery was required in less than 1% of all patients with diverticula^{6,7}. Surgery should typically be advised if an episode of complicated diverticulitis is treated nonoperatively and does not respond to nonoperative management⁸.

The complication of colonic diverticulitis represented by colovesical fistula is a relatively rare disease even in the western countries. The incidence of colovesical fistula in diverticular disease has been estimated to be approximately 2-4%, but has been reported to have a wide range between 2% and 23%. The most common cause of colovesical fistula is diverticulosis; however, it may be caused by malignant diseases, Crohn's disease, radiation, etc.¹⁴. The underlying mechanism is the direct extension of a ruptured diverticulum or secondary erosion of a diverticular abscess into the bladder^{9,10}. Pneumaturia or fecaluria are pathognomonic for the diagnosis of colovesical fistula, and it was detected in 71.4% and 51% cases, respectively, in which those complaints were found. On the other hand, a substantial number of patients present with frequent urination, dysuria, hematuria and other non-specific symptoms due to recurrent or persistent urinary tract infection; thus, the diagnosis of colovesical fistula may be delayed⁹. The aim of the diagnostic procedure for colovesicular fistula is to seek appropriate therapeutic strategy by assessing the existence of the fistula and the underlying etiology. For patients

who present with the non-specific symptoms of colovesicular fistula, the presence of a fistula has to be assessed first. According to Kwon et al.¹¹, the average detection rate of fistulae is low: cystoscopy, 42.4%; cystography, 41.3%; barium enema, 35.3%; colonoscopy or sigmoid colonoscopy, 6.4%; and abdominal computed tomography, 30.8%. Nevertheless, recently, during an observation over a period of 48 hours immediately following the consumption of poppy seeds, the rate of the diagnosis of fistula was found to be higher than 90%^{9,12}. For cases in which the presence of a fistula is not clear, confirmation of the presence of fistula by using the inexpensive and simple poppy seed test, followed by tests to find the causatives, should be considered.

The rate of diagnosis of colovesicular fistula by using colonoscopy is as low as 6-8.5%^{9,11}. Nonetheless, it has advantages in that diverticulitis, cancer or inflammatory bowel diseases, which may be the cause, can be ruled out, and distal stenosis can be assessed. Concerning surgeries for colovesicular fistula caused by locally progressed cancer, a wide bowel resection and a resection of the bladder wall together with adjacent lymph nodes is required. For colovesicular fistula caused by benign diseases, it is sufficient to resect the inflamed bowel and perform primary repair of the bladder wall. Therefore, preoperative colonoscopy is a prerequisite¹⁰. By cystoscopy, only non-specific findings, such as bullous edema, which suggests

a fistular tract, are shown, and the presence of a fistula is difficult to assess⁹. However, the relationship of the fistula to ureteral openings can be assessed. For cases with severe inflammation, in which injury to the ureter is, thus, a concern, a double J catheter may be inserted prior to surgery. Although rare, a colovesicular fistula caused by advanced bladder cancer may be detected. If air within the bladder is detected by abdominal computed tomography, and the adhesion of the colon to the bladder, as well as wall thickening, are shown, a colovesicular fistula can be diagnosed. Nonetheless, the diagnosis rate averages 30.8% and varies from 11 to 100%, depending on investigator. The wide variation in the detection rates is likely due to small sample size in each reported study. However, it could be of great help in planning surgery because it could assess the presence of an abscess and the anatomical relationship with adjacent structures, as well as the cause of fistula¹¹.

According to the treatment guidelines of the American Society of Colon and Rectal Surgeons, the recurrence of diverticulitis could be reduced if distally, the margin of resection were to be where the taenia coli splay out onto the upper rectum⁸. In our case, similarly, the resection was performed including that area. In cases of colovesicular fistula, the consensus on the treatment of a fistula on the side of the bladder has not been reached yet. According to Ferguson et al.¹², of 74 patients who developed a colovesicular fistula due to benign diseases, for 50 patients (67.6%) whose fistula was too small to detect, suture was not performed, and for the remaining patients, primary suture was performed; after placing the omentum between the bladder and the colon, followed by use of a Foley catheter for 1 week, a colcutaneous fistula and a vesicocutaneous fistula developed in only one case. Therefore, for cases in which the fistula cannot be seen distinctly, a partial resection of the bladder in the vicinity of the fistula and suture are not required. Conventionally, catheters are installed for 2 weeks and are removed after assessing the leakage by cystography. Nevertheless, in recent studies, installation of a catheter for longer than 1 week has been reported to increase complications, such as urinary tract infection, urine retention, bladder atony, etc., and a cystographic test is not required¹³. In our case, inflammation was severe, and the bladder was severely adhered to the colon over a wide area; thus, the fistula could not be found. The fistula was finally detected by performing a cystotomy. Inflammation was severe, a catheter was installed for 2 weeks and on day 14, cystography was performed. However, after cystography, sepsis developed temporarily. Considering retrospectively, if surgery had been performed after waiting for the inflammation to subside and the fistula to mature, the cystotomy could have been avoided, and the period of Foley catheterization could have been shortened.

In summary, as in our case, for patients presenting with fecaluria, pneumaturia and other specific symptoms of a

colovesicular fistula, Barium enema or cystography to confirm the presence of the fistula is not required; rather, finding the cause of the fistula and assessing the presence or absence of distal obstruction by performing abdominal computed tomography, colonoscopy, cystoscopy, etc. are important. During surgery, to prevent the recurrence of diverticulitis, the colon, including the upper rectum, should be resected distally. For the area of the bladder fistula, if inflammation is not severe, as in our case, primary suture and bladder rest by an indwelling urinary catheter is thought to be sufficient.

Riassunto

La diverticolosi del colon è in continuo incremento, in particolar modo nella porzione sinistra dello stesso. La fistola colovesicale è una complicanza poco comune della diverticolite ma la causa più comune è la diverticolite stessa. I sintomi più comuni sono la pneumaturia e la fecaluria.

Presentiamo il caso di una donna di 79 anni con fecaluria e pneumaturia la cui Tc addominale mostra una fistola colovesicale con una diverticolite del sigma.

Dopo aver effettuato chirurgicamente una adesiolisi tra il colon sigmoideo e la vescica, il difetto vescicale è stato chiuso con una chiusura diretta, mentre la parte di colon interessata dalla fistola è stata riparata con una resezione segmentaria che includeva la giunzione rettosigmoidea.

Il follow up eseguito a 6-12-18 mesi non ha evidenziato recrudescenze di malattia.

References

1. Kim SW, Park JS, Nam SB, Kim JJ, Kim SC: *Vesicosigmoidal fistula caused by diverticulitis*. Korean J Urol, 2005; 46:1221-223.
2. Kim HC, Yang DM, Lee SH, Joo SH: *Ultrasonographic features of a colovesical fistula arising secondary to sigmoid colon diverticulitis. A case report*. J Korean Soc Ultrasound Med, 2008; 27:153-56.
3. Choi CS, Cho EY, Kweon JH, Lim PS, No HJ, Kim KH, et al: *The prevalence and clinical features of colonic diverticulosis diagnosed with colonoscopy*. Korean J Gastrointest Endosc, 2007; 35:146-51.
4. Heise CP: *Epidemiology and pathogenesis of diverticular disease*. J Gastrointest Surg, 2008; 12:1309-311. [PubMed]
5. Song JH, Huh JG, Kim YS, Lee JH, Jang WC, Ok KS, et al: *Clinical characteristics of colonic diverticular disease diagnosed with colonoscopy*. Intest Res, 2008; 6:110-15.
6. Roberts PL, Veidenheimer MC: *Current management of diverticulitis*. Adv Surg, 1994; 27:189-208. [PubMed]
7. Somasekar K, Foster ME, Haray PN: *The natural history diverticular disease: is there a role for elective colectomy*. J R Coll Surg Edinb; 2002; 47:481-82. 484. [PubMed]

8. Rafferty J, Shellito P, Hyman NH, Buie WD: *Standards Committee of American Society of Colon and Rectal Surgeons. Practice parameters for sigmoid diverticulitis*. Dis Colon Rectum, 2006; 49:939-44. [PubMed]
9. Melchior S, Cudovic D, Jones J, Thomas C, Gillitzer R, Thuroff J: *Diagnosis and surgical management of colovesical fistulas due to sigmoid diverticulitis*. J Urol, 2009; 182:978-82. [PubMed]
10. Najjar SF, Jamal MK, Savas JF, Miller TA: *The spectrum of colovesical fistula and diagnostic paradigm*. Am J Surg, 2004; 188:617-21. [PubMed]
11. Kwon EO, Armenakas NA, Scharf SC, Panagopoulos G, Fracchia JA: *The poppy seed test for colovesical fistula: Big bang, little bucks!* J Urol, 2008; 179:1425-427. [PubMed]
12. Ferguson GG, Lee EW, Hunt SR, Ridley CH, Brandes SB: *Management of the bladder during surgical treatment of enterovesical fistulas from benign bowel disease*. J Am Coll Surg, 2008; 207:569-72. [PubMed]
13. de Moya MA, Zacharias N, Osbourne A, Butt MU, Alam HB, King DR, et al.: *Colovesical fistula repair: Is early Foley catheter removal safe?* J Surg Res, 2009; 156:274-77. [PubMed]
14. Tonelli F, Di Carlo V, Liscia G, Serventi A: *La malattia diverticolare del colon: quando e come trattarla*. Ann Ital Chir, 2009; 80: 003-8.

ERRATA - CORRIGE

Nella “Lettera al Direttore” *Evaluation and management of the CRPS II* di Monacelli et al. pubblicato sul n. 6/2012 pag. 581-582 di “Annali Italiani di Chirurgia” è stato riportato in maniera errata il nome di uno degli Autori che devesi leggere MI Rizzo invece di Mi Rizzo.