

# Cholangioscopic management of intra hepatic papillomatosis unsuitable for surgical treatment



Ann. Ital. Chir., 2009; 80: 35-38

Luca Panier Suffat\*, Gianruggero Fronza\*\*, Valeria Maglione\*\*, Dorigo Righi\*\*\*, Andrea Doriguzzi\*\*\*, Alessandro Repici\*\*\*\* and Paolo De Paolis\*\*\*\*\*.

\* *Divisione di Chirurgia Generale, Ospedale Civile, Tortona, Italy*

\*\* *Divisione di Chirurgia Generale 7, ASO S. Giovanni Battista, Torino, Italy*

\*\*\* *Istituto di Radiologia, Università degli Studi di Torino, Italy*

\*\*\*\* *Istituto Clinico Humanitas, Rozzano (MI), Italy*

\*\*\*\*\* *Divisione di Chirurgia Generale, Ospedale Gradenigo, Torino, Italy*

## Cholangioscopic management of intra hepatic papillomatosis unsuitable for surgical treatment

**INTRODUCTION:** *Biliary papillomatosis can arise in any tract of the biliary tree and is characterized by multiple papillary proliferation of the epithelial cells.*

**CASE REPORT:** *A 65 years old woman was diagnosed being affected by biliary papillomatosis after many recurrent cholangitic episodes. Liver transplantation was excluded because of neoplastic degeneration with systemic involvement. After a percutaneous drainage and with palliative intent we performed an Argon plasma coagulation of the papillary lesions.*

**DISCUSSION:** *Clinical behaviour consists of recurrent cholangitic episodes and obstructive jaundice. There aren't specific radiological features, only mucobilia observed during an ERCP is pathognomonic. Biliary papillomatosis grow according to the sequence adenoma-carcinoma with malignant transformation and poor prognosis due to multifocality and high recurrence rate. Radical surgery and liver transplantation represents the gold standard. Among palliative procedures must be considered percutaneous management with drainage and stenting, and intraluminal brachytherapy with I 192.*

**CONCLUSION:** *We propose a palliative treatment with cholangioscopic Argon plasma coagulation of the biliary lesions that can be performed during a surgical exploration or a percutaneous management.*

**KEY WORDS:** Argon plasma coagulation, Biliary papillomatosis, Cholangioscopy, Biliary tumor.

## Introduction

Biliary Papillomatosis (BP) is a rare entity characterized by multiple papillary proliferations of the epithelial cells of the intra or extra hepatic bile ducts. Since the first case reported by Chappet in 1894<sup>1</sup> about 140 cases have been published in the world literature<sup>2</sup>. Biliary papillomatosis can arise in any tract of the biliary tree including gallbladder, ampullary region and pancreatic duct. Although the tumor has been considered benign it potentially grows according to the sequence adenoma-carcinoma; the prognosis may be poor because of the multifocality, the high recurrence rate and the frequent malignant transformation<sup>3</sup>.

## Case report

In March 2001 a 65 years old woman was admitted to our Division because of recurrent episodes of cholangitis. Her past medical history was uneventful except for a laparoscopic cholecystectomy and ERCP in 1994 because of choledocholithiasis. Ultrasound (US), successive abdominal tomography (TC) and cholangio magnetic resonance (MRC) revealed a dilatation of intra and extra hepatic biliary tree with a mass of uncertain features, about 2 centimeters in diameter, in the distal choledocus associated to microlithiasis and sludges. At laparotomy we found a dilatation of the common bile duct without lithiasis. The complete absence of stones was confirmed by an intraoperative cholangiography. An hepatico-jejunostomy was performed while the histological examination was negative for dysplastic degeneration. The post operative course was uneventful and the patient was discharged after 15 days. In May 2002 the patient was again submitted to our observation because of a new episode of obstructive jaundice. The preoperative imaging showed dilated intrahepatic ducts and a

*Pervenuto in Redazione Agosto 2008. Accettato per la pubblicazione Ottobre 2008.*

*For correspondence: Luca Panier Suffat, MD, Località Tellario 1, 10085 Pont Canavese (Torino) Italy (e-mail: luca.panier@libero.it).*

dilatation of the terminal main bile duct with a probable stenosis of the hepatico-jejunostomy. The patient underwent to percutaneous radiological biliary drainage and bilioplasty with improvement of clinical manifestation.

In April 2003 a new hospitalisation occurred because of a new cholangitic episodes. The patient underwent to a percutaneous drainage with cholangiografic finding of intrahepatic biliary ducts dilatation without stenosis of the hepatico-jejunostomy and with biliary wall thickening according to the suspect of a biliary papillomatosis (Fig. 1).

A percutaneous cholangioscopy allowed endoscopic biopsies and a complete evaluation of the extension of the papillary lesions. A 14 Fr drainage was left in site while the anatomopathological evaluation confirmed the diagnosis (Fig. 2).

During the hospital stay we have considered the possibility of liver transplantation but the option was excluded because of patient's age and about above all for the presence of a carcinoma diagnosed histologically with a systemic pathology.

In May 2003 was programmed a surgical revision of the hepatico-jejunostomy associated to intraoperative Argon laser coagulation of the papillary lesions. The At laparotomy were evidenced papillary lesions involving the main bile duct and extending to II and III order biliary ducts, having with infiltrative features in some tracts infiltrative features and was confirmed by a cholangioscopic exploration. A fibroscopic Argon plasma coagulation of the lesion's wall was performed and an Y Roux hepatico-jejunostomy was performed.

Histology gave a definitive diagnosis of intraductal papillomatosis associated to areas of infiltrative papillary carcinoma.

After 8 months a new Argon plasma treatment was made by a percutaneous cholangioscopy. A strict follow up was programmed, no further surgical treatment was performed and the patient died after 17 months because of multiple pulmonary metastases.

## Discussion

Biliary Papillomatosis affects middle-aged and old adults with a male-female ratio of 2:1 <sup>4</sup>. The disease involves the extrahepatic ducts alone in 58% of cases, both extra and intrahepatic ducts in 33% and only intrahepatic ducts in 9% <sup>5</sup>. Pathogenesis seems related to irritation and inflammation of the biliary tree (stones, ectopic tissue, reactive hyperplasia, anomalous arrangement of the biliary tree with pancreatic juice regurgitation) associated with dilatation leading to papillary proliferation of the bile duct cells <sup>6</sup>. As for other tumours of the biliary tract an association with an anomalous junction of pancreatobiliary ductal system (AJPBDS) has been theorised. Iwasaki reported a case of AJPBDS in which he found a mutation of the K-ras gene and p53 protein overexpression <sup>7</sup>. Many associations with various pathological conditions have been reported such as viral B and C cirrhosis <sup>8</sup>, recurrent pyogenic cholangitis, congenital choledocal cyst, Caroli disease, polyposis coli and ulcerative colitis <sup>9</sup>.

According to recent evidence in Literature intraductal papillary mucinous neoplasm of the pancreas (IPMN), biliary papillomatosis and papillary cholangiocarcinoma are considered the same disease spectrum of papillary neoplasms of the pancreatobiliary system characterized by mucinous hypersecretion and mucobilia <sup>10</sup>.

Clinical presentation consists on relapsing attacks of

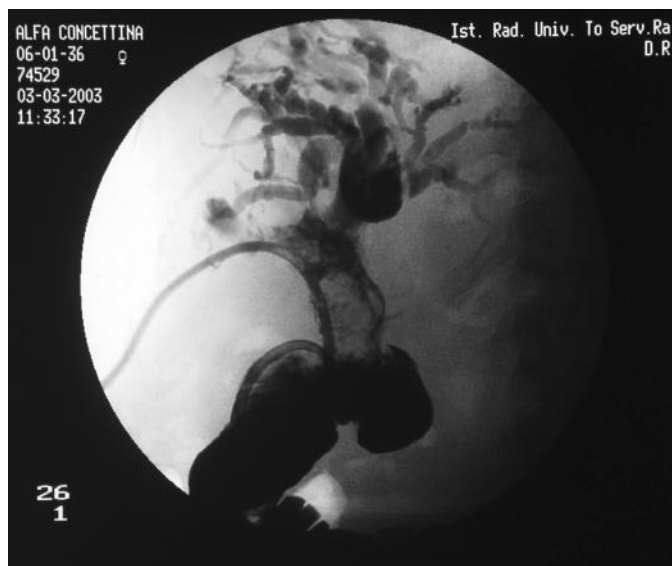

Fig. 1: Cholangiography that evidences dilatation of intra and extrahepatic bile ducts.

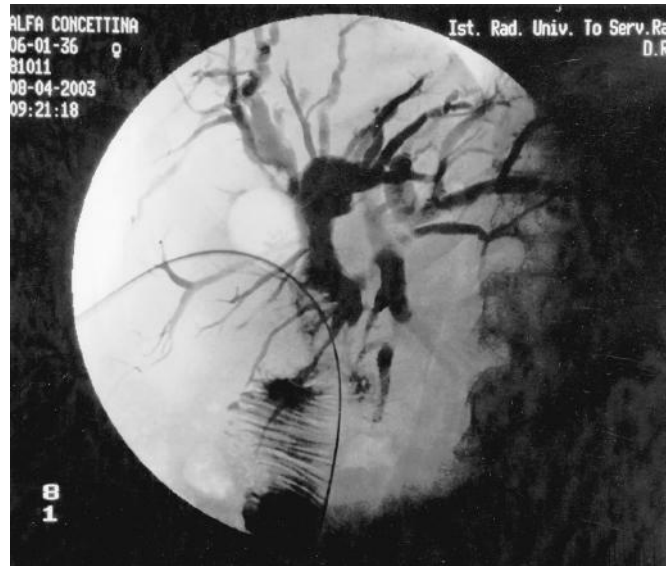


Fig. 2: Cholangiography with multiple intraductal sessile filling defects

obstructive jaundice, recurrent cholangitic episodes often with right-sided abdominal pain. Intermittent and repeated obstruction of the biliary tree is caused by mucus secretion, enlarging papilloma, amputation or fragmentation of the lesions.

Lee et al, in one of the greatest series reported, classified BP as mucin-hypersecreting and non producing accordingly with the presence of mucobilia found during endoscopy<sup>11</sup>. Preoperative diagnosis is usually difficult. No specific radiological features have been described. The most commonly encountered image is a dilatation of intra and extrahepatic bile ducts, wise wide, narrowing and multiple intraductal sessile filling defects that are ill-defined, irregular and fuzzy<sup>12</sup>. Diagnosis is possible thanks to US and CT findings completed by ERCP and sometimes by Percutaneous Transhepatic Cholangiography (PTC)<sup>13</sup>. However, obstruction is often related to a large amount or mucus secreted by the lesions that prevent opacification of the entire biliary tract. The inadequate inflow of the contrast material may fail to detect small papillomas, usually remote from the main lesion so these may be foci of recurrence. In these cases MR Cholangiography (MRCP) can be useful in the visualisation of the all biliary tree<sup>14</sup>. On the other hand ERCP and PTC allow therapeutic biliary drainage, stent insertion, brushing and biopsy<sup>15</sup>. MRCP is also useful for follow-up, that must be strict, to evaluate changes in lesion's characteristics and to determinate if someone new appears. Lai et al<sup>16</sup> report that endoscopic ultrasonography (EUS) significantly underestimate the extent of the intrahepatic disease, so many Authors suggest intraoperative cholangioscopic examination to identify concomitant subtle mucosal lesions, to have an histological diagnosis and "mapping" to decide whether or which type of resection is required<sup>17</sup>.

Yeung et al<sup>4</sup> in a recent review of the English literature shows an high rate of malignant occurrence of approximately 41%. Lee<sup>11</sup> reports that in 83% of 58 patients with BP a coexisting carcinoma was diagnosed after taking cholangioscopic biopsies from adenomas or examining histologically the surgical specimens.

In our patient coexisted adenomatous papillomas and invasive papillary adenocarcinoma giving a further documentation of progression from benign to malignant lesions. Surgical resection is the treatment of choice. The extent and the localization of the disease is established according to the pre operative imagine working and the intraoperative ultrasound or cholangioscopic mapping. The high recurrence rate after surgery is due to the multicentricity of the disease. If the patient can't undergo to major surgery or in case of impossibility of radical resection, must be considered palliative procedure like local ablation, stenting and drainage<sup>18</sup>.

Nowadays, because of the high risk of malignant transformation and recurrence, the gold standard of treatment, when possible, seems being liver transplantation, in these cases explanted liver must undergo histologic exam-

ination to exclude the presence of malignant degeneration<sup>19-20</sup>.

Lee et al reported a 5-years survival rate of 81% after curative resection, while in patients undergoing palliative drainage the mean survival is 37 months, significantly longer than that of cholangiocarcinoma.

In literature, among palliative procedures, there is a case report of an improved survival after intraluminal iridium 192 therapy in one patient with bilobar papillomatosis<sup>21</sup>.

The intraluminal brachiterapy, alone or combined with external radiotherapy or bilobar stenting, is useful in improving palliation and extending survival in patients with advanced bile duct cancer<sup>22</sup>.

Among palliative therapy we have considered that Argon plasma coagulation could be an optimal application in the evidenced papillary lesions<sup>23,24</sup>.

Our patient was not submitted to surgical resection because of the bilobar diffusion of the lesions, while liver transplantation was excluded because of the advanced age and presence of a systemic pathology. We chose an Argon plasma coagulation of the evidenced papillary lesions to avoid obstruction of the bile duct by mucus or tumour fragmentation leading to cholangitis, the treatment was performed the first time intraoperative and the second one by a percutaneous cholangioscopy.

Probably this is first report of treatment with Argon plasma coagulation and improved survival of an advanced papillomatosis with bilobar extent and without possibility of liver transplantation.

## Conclusion

Actually biliary papillomatosis should be considered a low grade neoplasm with high malignant potential, the clinical behaviour is characterized by an high recurrence rate and an higher malignant transformation occurrence. Therefore the local ablation is not adequate for this malignant disease, actually radical surgery is recommended as the only curative treatment options and liver transplantation is considered the gold standard.

In the presence of an advanced tumor the strategy to obtain an efficace palliative therapy could be a multidisciplinary approach. The colangioscopic Argon plasma coagulation of the papillary lesion utilised intraoperative or by a percutaneous approach to prevent cholangitis episodesan is a useful method to control neoplastic progression and systemic complications.

## Riassunto

INTRODUZIONE: La papillomatosi biliare può interessare ogni tratto dell'albero biliare ed è caratterizzata dalla proliferazione delle cellule epiteliali a formare multiple strutture papillari.

CASO CLINICO: Una paziente, di 65 anni, in seguito ad episodi ricorrenti di colangite, è stato diagnosticato essere affetta da papillomatosi biliare. Il trapianto epatico è stato escluso per la presenza di una neoplasia in stadio avanzato. Successivamente ad un drenaggio percutaneo è stato instaurato un trattamento palliativo con Argon plasma.

DISCUSSIONE: La storia clinica della malattia è caratterizzata da episodi ricorrenti di colangite ed ittero. Non esistono caratteristiche radiologiche peculiari, solo la presenza di mucobilia all'ERCP è patognomonica. Le lesioni si accrescono secondo la sequenza adenoma-carcinoma con scarsa prognosi dovuta alla multifocalità ed all'alta incidenza di recidive.

L'intervento chirurgico radicale ed il trapianto epatico sono considerati il gold standard. In caso di palliazione bisogna considerare un approccio percutaneo con drenaggio e posizionamento di stent, esiste inoltre una brachiterapia intraluminale con I 192.

CONCLUSIONI: Noi proponiamo un trattamento colangioscopico mediante coagulazione con Argon plasma che può essere eseguito intraoperatoriamente o mediante accesso percutaneo.

## References

- 1) Chappet V: *Cancer epithelial primitive du canal choledoque*. Lyon Med, 1894; 76:145-57.
- 2) Aoki S, Okayama Y, Kitajima Y, Hayashi K, Imai H et al: *Intrahepatic biliary papilloma morphologically similar to biliary cystadenoma*. J Gastroenterol Hepatol, 2005; 20:321-24.
- 3) Lam CM, Yuen ST, Yuen WK, Fan ST: *Biliary papillomatosis*. Br J Surg, 1996; 83(12):1715-716.
- 4) Yeung YP, AhChong K, Chung CK, Chun AY: *Biliary papillomatosis: Report of seven cases and review of English literature*. J Hepatobiliary Pancreat Surg, 2003; 10(5):390-95.
- 5) Chung DJ, Lee SK, Ha HK, Kim PN, Lee MG: *Multiple biliary papillomatosis: comparison of MR Cholangiography with Endoscopic Retrograde Cholangiography*. J Comput Assist Tomogr, 2002; 26(6):968-74.
- 6) Cheng MS, AsChong AK, Mak KL, Yip AW: *Case report: Two cases of biliary papillomatosis with unusual associations*. J Gastroenterol Hepatol, 1999; 14(5):464-67.
- 7) Iwasaki Y, Shimoda M, Furihata T, Rokkaku K, Sakuma A et al: *Biliary papillomatosis arising in a congenital choledochal cyst: Report of a case*. Surg Today, 2002; 32(11):1019-22.
- 8) Mourra N, Hannoun L, Rousvoal G, Parc R, Flejou JF: *Malignant intrahepatic biliary papillomatosis associated with viral C cirrhosis*. Arch Pathol Lab Med, 2002; 126:369-71.
- 9) Lee PSF, Auyeung KM, To KF, Chan YI: *Biliary papillomatosis complicating recurrent pyogenic cholangitis*. Clinical Radiology, 2001; 1-3.
- 10) Zen Y, Fujii T, Itatsu K, Nakamura K, Minato H et al: *Biliary papillary tumors share pathological features with intraductal papillary mucinous neoplasm of the pancreas*. Hepatology, 2006; 44(5):1333-343.
- 11) Lee SS, Kim MH, Lee SK, Jang SJ, Song MH et al: *Clinicopathologic review of 58 patients with biliary papillomatosis*. Cancer, 2004; 100(4):783-93.
- 12) Kawakatsu M, Vilgrain V, Zins M, Vullierme M, Belghiti J et al: *Radiologic features of papillary adenoma and papillomatosis of the biliary tract*. Abdom Imaging, 1997;22(1):87-90.
- 13) Sotiropoulos GC, Lang H, Nadalin S, Holtmann G, Dirsch O et al: *Papillomatosis confined to the distal biliary tract: A rare case of obstructive jaundice: report of a case*. Surg Today, 2003; 33(10):781-4.
- 14) Ma KF, Lu PP, Chau LF, Ah Chong AK, Lam HS: *Clinical and radiological features of biliary papillomatosis*. Australian Radiol, 2000; 44:169-73.
- 15) Ta-Sen Y, Jeng-Hwei T, Cheng-Tang C, Nai-Jen L, Tse-Ching C et al: *Cholangiographic spectrum of intraductal papillary mucinous neoplasm of the bile ducts*. Ann Surg, 2006; 244(2):248-53.
- 16) Lai R, Freeman ML, Mallery S: *EUS in multiple biliary papillomatosis*. Gastrointest Endoscopy, 2002; 55(2):121-25.
- 17) Kim YS, Myung SJ, Lee SK, Kim MH: *Role of percutaneous transhepatic cholangioscopy in biliary papillomatosis: Can it change treatment modality?* Gastrointest Endosc, 1998; 47:563-64.
- 18) Vassiliou I, Kairi-Vassilatou E, Marinis A, Theodosopoulos T, Arkadopoulou N et al: *Malignant potential of intrahepatic biliary papillomatosis: A case report and review of the literature*. World J Surg Oncol, 2006; 7(4):71-76.
- 19) Cox H, Ma M, Bridges R, Debru E, Bathe O et al: *Well differentiated intrahepatic cholangiocarcinoma in the setting of biliary papillomatosis: A case report and review of the literature*. Can J Gastroenterol, 2005; 19(12):731-33.
- 20) Invriou G, Papanikolaou V, Lalountas M, Patsiaoura K, Giakoustidis D et al: *Papillomatosis of intra and extrahepatic biliary tree: Successful treatment with liver transplantation*. Liver Transpl, 2007; 13(7):1045-48.
- 21) Gunven P, Gorsetman J, Ohlsen H, Ruden BI, Lundell G et al: *Six-year recurrence free survival after intraluminal iridium-192 therapy of human bilobar biliary papillomatosis. A case report*. Cancer, 2000; 89(1):69-73.
- 22) Takamura A, Saito H, Kamada K, Hiramatsu K, Takeuchi S et al: *Intraluminal low-dose-rate 192 Ir brachytherapy combined with external beam radiotherapy and biliary stenting for unresectable extrahepatic bile duct carcinoma*. Int J Radiat, Oncol Biol Phys, 2003; 57(5):1357-365.
- 23) Malick KJ: *Clinical applications of argon plasma coagulation in endoscopy*. Gastroenterol Nurs, 2006; 29(5):386-91.
- 24) Vargo JJ: *Clinical applications of the argon plasma coagulator*. Gastrointest Endosc, 2004; 59(1):81-88.